

OPEN ACCESS ATLAS OF OTOLARYNGOLOGY, HEAD & NECK OPERATIVE SURGERY



MYRINGOTOMY WITH VENTILATION TUBE INSERTION

Tashneem Harris & Thomas Linder

Ventilation tubes (grommets) are generally inserted for refractory middle ear effusions with persistent conductive hearing loss, present for a minimum duration of 3 months and with hearing loss exceeding 25dB. They may also be inserted as an adjunct procedure in acute mastoiditis secondary to acute suppurative otitis media.

Preoperative assessment

- Pneumatic otoscopy to confirm the diagnosis
- Pure tone audiometry within the preceding 3 months, or age appropriate hearing test, as well as tympanometry
- A middle ear effusion may be caused by pathology (benign or malignant) in the nasopharynx which causes tubal dysfunction. Therefore, particularly in adult patients the nasopharynx should be examined and the neck palpated for metastases from a nasopharyngeal malignancy
- A CSF leak may present as a middle ear effusion. A high index of suspicion is therefore necessary in the presence of a clear serous or watery effusion or when the history is suggestive of a CSF leak.

Surgical technique

Temporary ventilation tube insertion

- General anaesthesia is used for children
- Local anaesthesia may be employed with adults. Topical anaesthetic spray (e.g. xylocaine) can be applied to the tympanic membrane 10 minutes before the procedure. Alternatively, Emla cream® (lidocaine 2.5% and prilocaine 2.5%) can be applied to the tympanic

membrane 30 minutes prior to the procedure, or the deep ear canal may be injected with local anaesthesia with a dental needle

- An ear speculum is introduced into the ear canal and held in place with the left hand (Right-handed surgeon) (*Figure 1*)

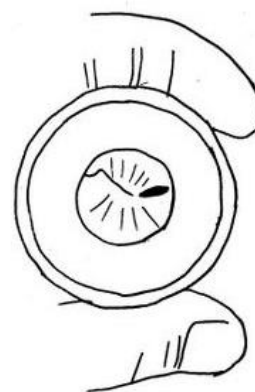


Figure 1: Ear speculum in place right ear with radial incision placed anteroinferiorly

- Using an operating microscope, a radial incision is made in the antero-inferior quadrant around the region of the light reflex with a myringotomy knife (*Figures 1 & 2*). Incisions in the posterosuperior quadrant are avoided as they could injure the ossicular chain or the chorda tympani. The incision must be large enough to accommodate a ventilation tube.

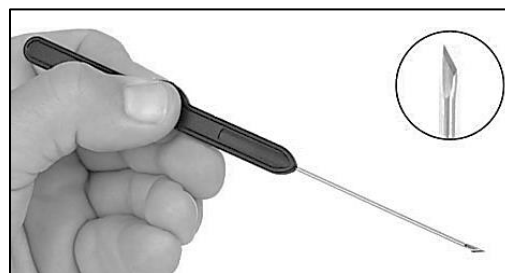


Figure 2: Typical myringotomy knife

- The middle ear effusion may be aspirated with a microsuction tube before inserting the grommet
- A ventilation tube is picked up with crocodile forceps and introduced into the ear canal using the right hand (*Figure 3*)



Figure 3: Examples of short stay tubes

- The tube is placed on the tympanic membrane adjacent to the myringotomy opening (*Figure 4*)

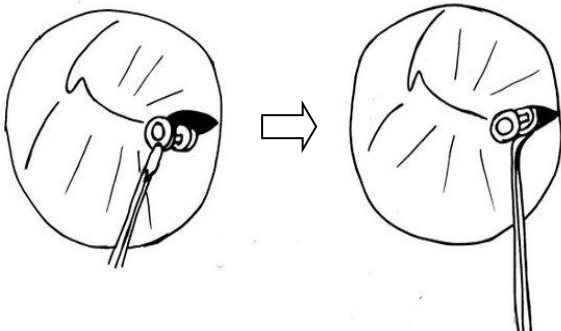


Figure 4: Placement of tube on right tympanic membrane, followed by advancement of tube with a hook

- Using a 1,5mm, 45° hook the inner flange is rotated through the myringotomy incision so that the tube straddles the tympanic membrane (*Figure 4*)

Long-term ventilation tube insertion

For long-term middle ear ventilation a ventilating T-tube is used (*Figure 5*). It remains in place for up to 3 years. After extrusion or removal it results in a chronic perforation of the tympanic membrane in about 16-19% of cases.^{2,3}



Figure 5: Example of a T-tube

- The flanges of the T-tube are grasped with crocodile forceps
- The flanges are then trimmed so that the ends are pointed; this facilitates insertion of the tube through the myringotomy opening (*Figure 6*)



Figure 6: The flanges are both trimmed

- A myringotomy is made in the antero-inferior quadrant of the tympanic membrane (*Figure 1*)
- The T-Tube is grasped with a fine crocodile forceps and the pointed end of the flange is inserted through the myringotomy incision

Special problem: Ventilation tube falls into middle ear

- Although tubes are inert and are unlikely to cause damage when left in the middle ear, removal should be attempted because of the potential for foreign body reaction.⁴
- If the grommet lies close to and can be seen through the myringotomy incision, then it may be possible to retrieve it using small crocodile forceps, and then reinserted correctly

- If the tube however lies beyond the confines of the mesotympanum, cannot be seen and removal would be difficult, then one option is to leave it *in situ* and for the patient to return regularly for surveillance and otomicroscopy⁴
- Surgical removal when one has a healed, intact tympanic membrane entails a wide myringotomy and removal of ventilation tube
- Very rarely an exploratory tympanotomy may be required

References

1. Fisch U, May J. Tympanoplasty, Mastoidectomy and Stapes Surgery. New York: Thieme; 1994
2. Van Heerbeek N, De Saar GM, Mulder JJ. Long term ventilation tubes: results of 726 insertions. *Clin Otolaryngol Allied Sci.* 2002;27(5): 378-83
3. Kay DJ, Nelson M, Rosenfeld RM. Meta-analysis of tympanostomy tube sequelae. *Otolaryngol Head Neck Surg.* 2001;124(4):374-80
4. Rosenfeld RM, Bluestone CD. Evidence Based Otitis Media. 2nd Ed. Hamilton: BC Decker Inc; 2003

Author

Tashneem Harris MBChB, FCORL, MMED (Otol), *Fisch Instrument Microsurgical Fellow*
 ENT Specialist
 Division of Otolaryngology
 University of Cape Town
 Cape Town, South Africa
harristasneem@yahoo.com

Senior Author

Thomas Linder, M.D.
 Professor, Chairman and Head of
 Department of Otorhinolaryngology,
 Head, Neck and Facial Plastic Surgery
 Lucerne Canton Hospital, Switzerland
thomas.linder@ksl.ch

Editor

Johan Fagan MBChB, FCORL, MMed
 Professor and Chairman
 Division of Otolaryngology
 University of Cape Town
 Cape Town, South Africa
johannes.fagan@uct.ac.za

**THE OPEN ACCESS ATLAS OF
 OTOLARYNGOLOGY, HEAD &
 NECK OPERATIVE SURGERY**
www.entdev.uct.ac.za



The Open Access Atlas of Otolaryngology, Head & Neck Operative Surgery by [Johan Fagan \(Editor\)](mailto:johannes.fagan@uct.ac.za) johannes.fagan@uct.ac.za is licensed under a [Creative Commons Attribution - Non-Commercial 3.0 Unported License](https://creativecommons.org/licenses/by-nc/3.0/)

